

RESULTS OF SELECTIVE CAPSULOTOMY AND SUPRASPINATUS TENDON REPAIR IN PATIENTS WITH DIABETES (RETROSPECTIVE STUDY)

^aSERHII STRAFUN, ^bSERHII BOHDAN, ^cOLEKSANDR STRAFUN, ^dLYUBOMYR YURIYCHUK, ^eVOLODYMYR BILIAVSKYI

^{a-c-e}SI "The Institute of Traumatology and Orthopedics" by NAMS of Ukraine, 27, Bulvarno-Kudriavska Str., 01601, Kyiv, Ukraine
^dIvano-Frankivsk Regional Clinical Hospital, 91, Fedkovich Str., 76000, Ivano-Frankivsk, Ukraine
 email: ^astrafun-s@ukr.net, ^bsergey-mena@ukr.net, ^co_strafun@ukr.net, ^dtrauma.okl@gmail.com, ^edr.biliavskiy@gmail.com

Abstract: The article describes selective capsulotomy for RC repair in DM patients with RC tendon ruptures. The results of surgery and post-op follow-up in 3 and 6 months after surgery for two groups of patients (the group who underwent arthroscopic selective capsulotomy of the shoulder joint and the group who did not undergo selective capsulotomy) are presented. The total size of sample of included patients was 110 participants. The function of the shoulder joint was evaluated using the Constant Shoulder Score and VAS. Descriptive statistics methods were used to display the general characteristics of the initial parameters, indicating the average value and standard deviation. Patients with type 2 diabetes who underwent supraspinatus tendon suture and selective capsulotomy had better average functional results 3 months after surgery on the Constant Shoulder Score and VAS scale, and in 6 months patients who underwent selective capsulotomy reported better level of VAS pain syndrome.

Keywords: Shoulder joint, Tendon ruptures, Capsulotomy, Diabetes mellitus.

1 Introduction

Ruptures of rotator cuff of the shoulder (RC) range from 18% to 36% among all shoulder joint injuries [6, 9, 16]. In at least 40% of cases, RC tendon ruptures are accompanied by a contracture of the shoulder joint [13, 18]. The main causes of post-traumatic contracture in patients with RC tendon rupture are considered to be pain, hemarthrosis or inflammatory changes in the capsule of the shoulder joint [6, 9, 18]. During arthroscopy in such patients, we can detect inflammatory changes and thickening of the capsule of the shoulder joint. The frequency of contracture after RC repair (so-called post-immobilization contracture) ranges from 4.9% to 23% [13, 18].

Patients with diabetes mellitus (DM) have a greater tendency to develop contractures in the shoulder joint. In this case, adhesive capsulitis is diagnosed. Contracture of the shoulder joint in patients with diabetes occurs with a frequency from 10% to 41.7% [4], while in the general population it ranges from 2–5% [1, 15, 16].

The debatable issue is if we need to perform selective shoulder capsulotomy during RC repair in patients with DM. On the one hand, the thickened capsule and the contracture of the shoulder joint have a positive effect on the RC healing, and the long-term results after one year of observation have no differences in patients who underwent selective capsulotomy and who did not undergo this procedure [2, 13, 8, 11]. On the other hand, a contracture that lasts for a long time leads to hypotrophy of the RC and deltoid muscles, decrease of bone density, and degenerative changes in the articular cartilage [4, 16].

Some authors recommend staged treatment: on the first stage - conservative treatment of adhesive capsulitis, on the second stage - the suture of the RC tendons [19]. However, this approach significantly prolongs the duration of treatment, and in patients with diabetes mellitus, it can lead to a series of complications (infection after injections in shoulder joint, fractures during redressing procedure, separation of the scapula labrum, formation of rotator cuff arthropathy, etc.).

The aim of our study was to compare the results of treatment of patients with diabetes who underwent selective capsulotomy and those who did not undergo this procedure during RC repair.

2 Materials and Method

From 2015 to 2020, we performed 825 RC repairs in the clinic of Microsurgery, reconstructive and restorative surgery of the upper limb of the State Institution "Institute of Traumatology and Orthopedics of the National Academy of Medical Sciences of Ukraine" (Kyiv). Of these, 169 patients were with DM type 2, supraspinatus tendon rupture, and shoulder joint contracture of various degrees (restriction of passive movements in the shoulder joint). All 169 patients underwent arthroscopic double-row suture of the supraspinatus tendon and tenodesis of the long biceps head tendon. Part of these patients underwent arthroscopic selective capsulotomy of the shoulder joint (group 1), while another part did not undergo selective capsulotomy (group 2). All patients were warned about the specifics of their surgical intervention and gave informed written consent to perform the surgical intervention.

59 patients were excluded from the study: 37 patients did not find time for control observation and visit to a doctor in 3 months after the surgery; in 9 patients, there was a repeated rupture of the supraspinatus tendon within 3 months after the operation, which was discovered during ultrasound examination; 13 patients did not follow the standard rehabilitation program. We included into the study 110 patients who underwent full rehabilitation program and all stages of post op follow-up until 6 months after surgery. The average age of the patients was 51.4 ± 12.6 . All patients were divided into two groups (group 1 – with selective capsulotomy that was performed during RC repair, group 2 – without selective capsulotomy during supraspinatus tendon suture). The general characteristics of the groups are given in Table 1.

Table 1: Main characteristics of groups

Characteristic	Group 1 (n=74)	Group 2 (n=36)	p
Age	42.1±8.9	40.1±16.1	0.731*
Gender: male/female	39 (52.7%) / 35 (47.3%)	20 (55.6%) / 16 (44.4%)	0.182**
Tear size, mm	12.5±10.2	18.1±12.1	0.52*
Time from injury to surgery (months)	1.51±0.91	1.92±0.44	0.061***
Flexion angle in the shoulder joint before surgery	80.8±8.2	90.1±16.2	0.42*
Extension angle in the shoulder joint before surgery	8.8±10.1	15.1±6.1	0.71*
Abduction angle in the shoulder joint before surgery	20.7±18.2	31.1±14.4	0.74*

* — Student's criterion; ** — χ^2 criterion; *** — Mann-Whitney test.

In our study, we evaluated the function of the shoulder joint using the Constant Shoulder Score and VAS before surgery, in 3 and 6 months after surgery. According to the Constant Shoulder Score scale, the maximum number of points is 100, the minimum is 8. The injured and healthy upper limbs were compared. A difference of more than 30 points between two limbs was considered an unsatisfactory result, 21–30 points – a satisfactory result, 11–20 points – a good result, and less than 11 points – an excellent result [12].

All patients were examined clinically and radiologically, and all patients underwent an MRI examination. MRI studies of the anatomical structures of the shoulder joint, including the tendon of the supraspinatus muscle, were performed in the following modes: T1, T2, Pd and Pdfatsat.

In 4.1 ± 0.9 months after surgery, the patients underwent an ultrasound examination for assessing the supraspinatus muscle tendon healing. Ultrasound with multifrequency sensors were used (stationary Philips ATL 3500 and a portable Honda-2000). Optimal visualization was achieved using the "musculocutaneous superficialis" mode, which corresponded to a frequency of 7.5 MHz.

The criteria for inclusion in to the study were as follows:

- Injury of the shoulder in the anamnesis, age from 30 to 60 years,
- A full thickness rupture of the supraspinatus muscle tendon (from 15 to 30 mm, which we determined objectively with the help of an arthroscopic ruler (Fig. 1a)),
- Standard protocol of surgical intervention (double row RC repair),
- The duration of the disease from 10 to 100 days,
- Thickened capsule of the shoulder joint (Fig. 1b),
- Absence of concomitant pathology of the shoulder joint (omarthrosis, rupture of the scapula labrum, rupture of the subscapular muscle tendon, calcifying tendinitis of the RC tendons, any bone pathology of the proximal epimetaphysis of the humerus),
- Examinations of the patient after surgery in 3 and 6 months,
- Video record of surgery,
- Compliance to the terms of immobilization and rehabilitation programs.

Surgical technique: the patient was placed in the "beach chair" position with 2-3 kg traction on the affected limb, 5 arthroscopic portals were performed (2 into the shoulder joint, 2 into the subacromial space, 1 in the projection of the long biceps head tendon, which was later used as a port into the subacromial space). Intraoperative diagnosis was carried out using an arthroscope with a diameter of 4.5 mm with an optical tilt of 30°.

All patients underwent: tenodesis of the tendon of the long biceps head at the level of the intertuberos groove with fixation with a SwiveLock screw (diameter of 7-9 mm) (Fig. 1c), acromioplasty (Fig. 1d), subacromial bursectomy, synovectomy of the rotator interval. In group 1, dissection of the anterior and posterior parts of the shoulder joint capsule was performed using a vaporizer (Fig. 1e) or arthroscopic scissors (Fig. 1b). In addition, the following was applied: a double-row supraspinatus tendon repair using two BioComposite Corkscrew FT Suture Anchors, 5.5 mm x 14.7 mm in the proximal row and one BioComposite SwiveLock SP Self Punchsng with Titanium Eyelet in the distal row. In this way, we performed a double-row "V"-shaped RC repair (SpeedFix) (Fig. 1f).

After surgery, all patients in the operating room were immobilized in bandage with abduction pillow (angle of 20°). After 6 weeks, all patients began to perform a standard rehabilitation program. Exercises were performed three times a day for 30 minutes in the first 2 weeks under the supervision of a rehabilitation specialist, then by the patient independently for 30 minutes 3 times a day until a normal shoulder-scapular rhythm was achieved.

Statistical data processing was carried out using the Statistica 12 package (StatSoft, USA). Descriptive statistics methods were used to display the general characteristics of the initial parameters, indicating the average value and standard deviation. For variables with a normal distribution, group comparisons were performed using the Student's test. The condition of equality of variances was checked using the Livigno test. In order to determine the statistical significance of differences between groups, the Mann-Whitney test was used for quantitative (non-normally distributed) and ordinal variables,

and the χ^2 test and Fisher's exact test were used for qualitative ones. Comparison of quantitative and ordinal variables in dependent samples was performed using the Wilcoxon test.

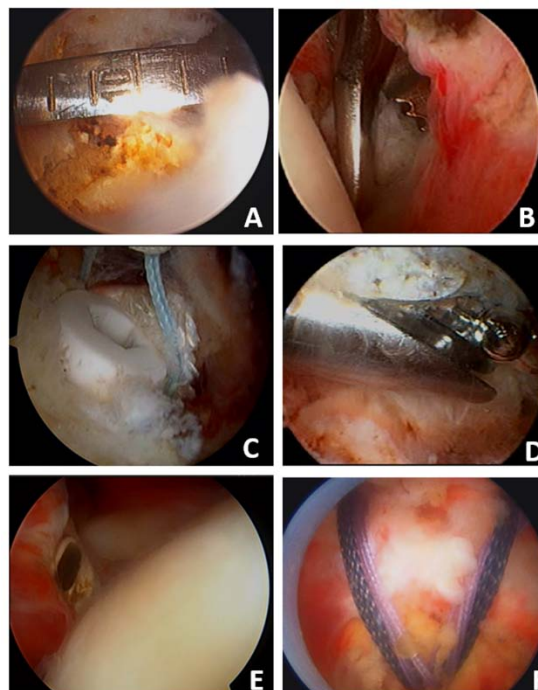


Figure 1. Stages of surgical intervention (explanation in the text).

3 Results

In Table 2 and Table 3, the average results of treatment of patients in two groups before surgery, 3 and 6 months after surgery are shown. Each time, patient independently filled out the form with the Constant Shoulder Score scale and VAS. The patient performed the test with a dynamometer until pain sensations appeared. Control of the correctness of all tests of the Constant Shoulder Score scale was performed by one doctor, who was an assistant during the surgical intervention.

Table 2: Average results of treatment of patients in groups 1 and 2 according to the Constant Shoulder Score at different periods of observation

Terms of examination of patients	Group 1 (n=74)	Group 2 (n=36)	P (Wilksion's criterion) †
Before the surgery	25.8±13.1	23.5±9.3	0.91
3 months after the surgery	15.5±7.2	19.5±6.1	0.33
6 months after the surgery	12.1±5.2	11.1±6.2	0.54

As one can see from Table 2, before surgery, the average results of shoulder joint function according to the Constant Shoulder Score in the two groups were practically the same and ranged within 24 points (the difference in scores between healthy and diseased shoulder joints). Three months after the surgery, in group 1, the average functional result on the Constant Shoulder Score was slightly better than in group 2 and ranged approximately 15.5 ± 7.2 points. Six months after surgery in groups 1 and 2, the average functional results on the Constant Shoulder Score scale did not differ and ranged from 11 to 12 points. We rated them as excellent. According to the VAS scale, we obtained the following results (Table 3).

As we can see from Table 3, before the surgical intervention, the average score of the pain syndrome of patients in groups 1 and 2 according to the VAS scale were practically the same and ranged from 3.6 to 3.8 points. Three months after the operation, in group 1, the average score on the VAS scale was slightly better than in group 2 and ranged approximately 1.55 ± 1.2 points. Six months after surgery, the mean VAS score in group 1 was also slightly better than in group 2.

Table 3: Average results of treatment of patients in groups 1 and 2 according to the VAS scale at different periods of observation

Terms of examination of patients	Group 1 (n=74)	Group 2 (n=36)	P (Wilkson's criterion) †
Before the surgery	3.8 ± 2.1	3.6 ± 1.8	0.9
3 months after the surgery	1.55 ± 1.2	1.91 ± 0.8	0.33
6 months after the surgery	1.8 ± 1.2	2.2 ± 1.3	0.5

Thus, patients in group 1 (suture of the supraspinatus tendon and selective capsulotomy) had better average functional results 3 months after surgery according to the Constant Shoulder Score scale and according to the VAS scale. At 6 months postoperatively, the Constant Shoulder Score scores were almost identical, but according to VAS patients in group 1 had better results.

4 Discussion

The issue of optimal treatment tactics for RC rupture and various concomitant pathologies of the shoulder joint in patients with DM remains relevant and understudied. This is related to the peculiarities of blood supply and regeneration of various parts of body, including tendons of the RC in patients with DM.

Most of the studies conducted by our colleagues, comparing the results of selective capsulotomy in patients with contracture of the shoulder joint that occurred after RC rupture, do not take into account the presence of diabetes or any other pathology that may negatively affect rehabilitation [6, 9, 18]. In their studies, the results of treatment in patients who underwent selective capsulotomy and in patients who did not undergo this procedure were almost the same 12 months after the surgery [6, 9, 18].

H.S. Park and co-authors in their study indicate that the results of selective capsulotomy in patients who underwent RC repair one year after surgery are better than in the group where selective capsulotomy was not performed [14]. Also, it is interesting that this work proves the need for only anterior and anteroinferior capsulotomy and excludes the need for posterior capsulotomy, which reduces the duration of surgical intervention [14].

In the work of Y.S. Kim and co-authors, the results of early and delayed surgical interventions are compared, in which the authors performed a RC repair and a selective capsulotomy. It has been proven that early and delayed surgical interventions show the same results 12 months after surgery, so it does not make sense to carry out long-term conservative treatment in patients with RC tendon rupture and secondary adhesive capsulitis [14].

The issue of treatment of shoulder joint contracture in patients with DM can be considered solved, since a huge number of works indicate positive results of selective capsulotomy under arthroscopic control in this group of patients [12]. Despite this, the results of RC repair in patients with DM and secondary adhesive capsulitis remain uncovered.

In the study of J.Y. Park et al., it is indicated that the results of selective capsulotomy in combination with the RC repair in patients with diabetes were better than the results of the

supraspinatus tendon suture without selective capsulotomy, however, this study was conducted on only 15 patients and needs to be continued [13].

The strengths of our study is that in our work we evaluated the results of selective capsulotomy of the shoulder joint both by the objective scale (Constant Shoulder Score) and by the subjective scale (VAS); we managed to create statistically identical study groups which are clearly determined by the type of diabetes, age, and size of the supraspinatus tendon rupture.

The weaknesses of our study is that we did not take into account the specific level of blood sugar before surgery and during rehabilitation in our patients, the lack of control over the exercise during rehabilitation program. Also, we did not take into account other concomitant pathology (coronary heart disease, hypertensive disease etc.), which can negatively affect the rehabilitation of patients.

5 Conclusion

Patients with type 2 diabetes who underwent supraspinatus tendon suture and selective capsulotomy had better average functional results 3 months after surgery on the Constant Shoulder Score and VAS scale ($p=0.33$). Six months after surgery, the Constant Shoulder Score results were almost the same in the two groups, but the VAS pain syndrome level in the group that underwent selective capsulotomy was better ($p=0.5$).

Literature:

1. Cho, C.H., Koo, T.W., Cho, N.S., et al. (2015). Demographic and clinical characteristics of primary frozen shoulder in a Korean population: a retrospective analysis of 1,373 cases. *Clinics in Shoulder and Elbow*, 18, 133-137. DOI: 10.5397/cise.2015.18.3.133
2. Cho, N.S., & Rhee, Y.G. (2008). Functional outcome of arthroscopic repair with concomitant manipulation in rotator cuff tears with stiff shoulder. *American Journal of Sports Medicine*, 36, 1323-1329. DOI: 10.1177/0363546508314402
3. Chung, S.W., Oh, J.H., Gong, H.S., Kim, J.Y., Kim, S.H. (2011). Factors affecting rotator cuff healing after arthroscopic repair: osteoporosis as one of the independent risk factors. *American Journal of Sports Medicine*, 39, 2099-2107. DOI: 10.1177/0363546511415659.
4. Itoi, E., Arce, G., Bain, G. I., Diercks, R. L., Guttman, D., Imhoff, A. B., Mazzocca, A. D., Sugaya, H., & Yoo, Y.-S. (Eds.) (2015). *Shoulder stiffness: Current concepts and concerns*. Springer. <https://doi.org/10.1007/978-3-662-46370-3>
5. Kang, S.W. (2019). Do we have to perform surgical treatment simultaneously for rotator cuff tear in patients with adhesive capsulitis. *Korean Journal of Sports Medicine*, 37, 11-16. doi.org/10.5763/kjms.2019.37.1.11
6. Kelly, J. D. (2016). *Elite Techniques in Shoulder Arthroscopy*. Springer. DOI 10.1007/978-3-319-25103-5
7. Kim, Y.S., Lee, H.J., Park, I., Im, J.H., Park, K.S., Lee, S.B. (2015). Are delayed operations effective for patients with rotator cuff tears and concomitant stiffness? An analysis of immediate versus delayed surgery on outcomes. *Arthroscopy*, 31, 197-204. doi: 10.1016/j.arthro.2014.08.014.
8. Kim, I.-B., & Jung, D.-W. (2018). A Rotator Cuff Tear Concomitant With Shoulder Stiffness is Associated With a Lower Retear Rate After 1-Stage Arthroscopic Surgery *American Journal of Sports Medicine*, 46(8), 1909-1918. doi: 10.1177/0363546518768813.
9. McMahon, P. J. (2017). *Rotator Cuff Injuries A Clinical Casebook*. Springer. DOI 10.1007/978-3-319-63668-9
10. McGrath, J.P., Lam, P.H., Tan, M.T., Murrell, G.A. (2016). The effect of concomitant glenohumeral joint capsule release during rotator cuff repair - a comparative study. *Journal of Shoulder and Elbow Surgery*, 25, 714-722. DOI: 10.1016/j.jse.2015.10.005.
11. Oh, J.H., Kim, S.H., Lee, H.K., Jo, K.H., Bin, S.W., Gong, H.S. (2008). Moderate preoperative shoulder stiffness does not alter the clinical outcome of rotator cuff repair with arthroscopic release and manipulation. *Arthroscopy*, 24, 983-991. DOI: 10.1016/j.arthro.2008.06.007

12. Park, J.Y., Pandher, D.S., Moon, G.H., Yoo, M.J., Lee, S.T. (2008). Comparison of surgical outcome in impingement syndrome with and without stiff shoulder. *Indian Journal of Orthopaedics Surgery*, 42, 182-187. doi: 10.4103/0019-5413.40255.
13. Park, J.-Y., Chung, S., Hassan, Z., Bang, J.-Y., Oh, K. (2014). Effect of capsular release in the treatment of shoulder stiffness concomitant with rotator cuff repair: Diabetes as a predisposing factor associated with treatment outcome. *American Journal of Sports Medicine*, 42(4), 840-50. DOI: 10.1177/0363546513519326
14. Park, H.-S., Choi, K.-H., Lee, H.-J., Kim, Y.-S. (2020). Rotator cuff tear with joint stiffness: a review of current treatment and rehabilitation. *Clinics in Shoulder and Elbow*, 23(2), 109-117. doi: 10.5397/cise.2020.00143
15. Ramirez, J. (2019). Adhesive capsulitis: Diagnosis and management, *American Family Physician*, 99(5), 297-300.
16. Rockwood, Ch. A, & Matsen, F. A. (2016). *The Shoulder* (5th Ed.). Elsevier.
17. Sabzevari, S.A., Kachooei, R., Giugale, J., Lin, A. (2017). One-stage surgical treatment for concomitant rotator cuff tears with shoulder stiffness has comparable results with isolated rotator cuff tears: a systematic review. *Journal of Shoulder and Elbow Surgery*, 26(8), e252-e258. DOI: 10.1016/j.jse.2017.03.005
18. Tauro, J.C. (2006). Stiffness and rotator cuff tears: incidence, arthroscopic findings, and treatment results. *Arthroscopy*, 22, 581-586. DOI: 10.1016/j.arthro.2006.03.004
19. Warner, J.J., & Greis, P.E. (1998). The treatment of stiffness of the shoulder after repair of the rotator cuff. *Instructional Course Lectures*, 47, 67-75.
- Strickland, E. (1991). *American composers. Dialogues on Contemporary music*. Indiana University Press.

Primary Paper Section: F

Secondary Paper Section: FI, FJ, FB